

Systematic Review

Open Access

# Ocular Manifestation and Visual Outcome of Zika Virus Infection Associated with Congenital Zika Syndrome

Anak Agung Dewi Adnya Swari<sup>1</sup>, Ida Ayu Ary Pramita<sup>2</sup>, I Gusti Ayu Made Juliar<sup>2</sup>, I Made Ady Wirawan<sup>3</sup>

## Abstract

**Introduction:** Zika virus disease is an acute infectious disease caused by Zika virus transmitted through *Aedes* mosquitoes. The ocular findings in children with Zika virus, cause a broad spectrum of ocular manifestations and present up to 55% of affected infants. This review explores its ocular manifestations and visual acuity of Zika virus infection.

**Methods:** A systematic review was conducted in accordance with Preferred Reporting Items for Systematic Reviews and Meta-Analyses (PRISMA) from the PubMed databases. Assessment of study quality and risk of bias were assessed by using checklist from Joanna Briggs Institute (JBI).

**Results:** We included 9 literatures with most literatures came from Brazil. Zika virus result in various ocular manifestations, ranging to congenital glaucoma, microphthalmia, congenital cataract, lens subluxation, iris coloboma, and retinopathy. The ocular manifestations of Zika virus significant impact on visual outcome.

**Conclusion:** Children with Zika virus infection present of ophthalmological abnormalities and high risk for severe visual impairment.

**Keywords:** congenital Zika syndrome; systematic review; ocular manifestation; visual acuity outcome; Zika virus

## Correspondence:

Anak Agung Dewi Adnya Swari  
dewiadnya@gmail.com

1. Ophthalmology Resident, Ophthalmology Program Study, Faculty of Medicine, Udayana University, Prof. I.G.N.G. Ngoerah Hospital, Denpasar, Bali, Indonesia
2. Ophthalmologist, Department of Ophthalmology, Prof. I.G.N.G. Ngoerah Hospital, Denpasar, Bali, Indonesia
3. Department of Public Health and Preventive Medicine, Faculty of Medicine, Universitas Udayana, Denpasar, Bali, Indonesia

## Introductions

Zika virus is a flavivirus of the family Flaviviridae, isolated initially in non-human primates in Uganda (1947), and in humans (1954) in Nigeria, Africa. The first recorded outbreak was on the Yap Islands of Micronesia in 2007, followed by an epidemic in French Polynesia in 2013 and 2014. Brazil, the first cases of the disease were reported in May 2015. The cases of Zika virus infection have been documented over the course in Thailand, East Malaysia (Sabah), Cambodia, the Philippines, Indonesia, and Thailand.<sup>1</sup> Vertical transmission has been associated with spontaneous abortion and stillbirth, and also with congenital malformations in newborns including microcephaly. In 2015, when the virus arrived and

the first cases of microcephaly appeared, the prevalence rate to 54.6 per 100,000 live births. <sup>1</sup> Analyzing the possible risk factors associated with the ocular manifestations of Zika virus, Ventura et al identified a relationship between the ocular findings and the trimester of infection during pregnancy, where the first trimester was identified as risk factor for ocular findings.<sup>2</sup>

The ocular findings in children with Zika virus, may cause a broad spectrum of ocular manifestations and be present up to 55% of affected infants.<sup>1</sup> Additional ocular findings on infants reported congenital glaucoma, microphthalmia, congenital cataract, lens subluxation, and iris coloboma, optic disc hypoplasia, pallor, increased cup-to-disk ratio and the vascular manifestations include retinal hemorrhages and peripheral retinal vasculature

abnormalities. The ocular dysmotility identified in children with zika virus, strabismus and nystagmus were detected in 79.8% and 45.4% of the cases. Abnormal contrast sensitivity and visual field defect have been identified in 81.3% and 45.1% of the zika virus infection. All of these ocular manifestations in association with the structural abnormalities of the eye (anterior and posterior segments findings) in severe visual impairment of zika virus.<sup>3</sup>Ocular findings in addults during acute infection, was reported by Parke et al with unilateral acute maculopathy in a male adult infected of zika virus and resolved within 6 weeks. The most recent acute zika virus infection case reported in the literature described chorioretinitis lesions in an immunocompromised adult patient who evolved with scaring and improvement of vision.<sup>1</sup>

Children with zika virus infection found a high prevalence of severe visual impairment and observed 84.6% with normal structured eyes presented abnormal visual acuity and presente high risk of cortical/cerebral visual impairment regardless of ocular damage, probably due to severe cerebral malformation and abnormal brain development. Measures visual acuity and visual function were useful for evaluating severity of visual impairment.<sup>1,3</sup> The American Academy of Pediatrics, the American Association for Pediatric Ophthalmology and Strabismus, and the American Academy of Ophthalmology recommend that visual function and visual milestones be accessed in early children. It is important to recognize ocular manifestations in determining visual outcomes in children infected with Zika virus.

## Methods

This study was a systematic review conducted in accordance to Preferred Reporting Items for Systematic Reviews and Meta-Analyses (PRISMA) guidelines.

We searched database PubMed, Google

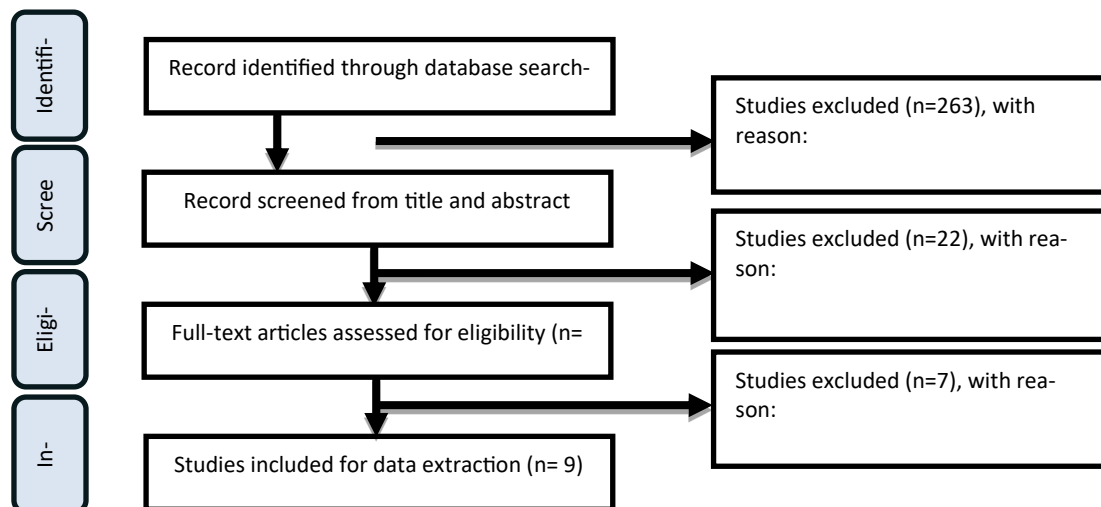


Figure 1. PRISMA Flow Chart of Study Selection

Scholar, Science Direct and Cochrane Library regarding ocular manifestation and visual acuity in Zika Virus. The studies being retrieved with following keywords were used during the literature searching: (“ocular” OR “ocular manifestation” OR “visual outcome” OR “eye” OR “ophthalmology” OR “ophthalmic”) AND (“Zika Virus”). We included all original studies regarding ocular manifestation and visual outcome of zika virus. Eye manifestations including visual acuity in this study occurred in Zika virus infection as proven on supporting examinations. We excluded studies conducted in non-human, review articles, letters, editorials, inaccessible full text, and studies which were not published in English language.

The data obtained from the study includes author’s name, year of publication, country of origin of the study, number of samples, the type of ocular manifestation, visual outcome, and ocular finding of segment. Study quality and bias risk were evaluated using the Joanna Briggs Institute (JBI) criteria. The checklist’s items each counted for one point. When a study receives at least half of the maximum possible points, it is said to be of high quality. When it receives fewer than half of the possible points, it is deemed to be of low quality. In order to prevent bias, two reviewers independently assessed the study’s quality. Two reviewers’ disagreement was resolved by consensus.

## Results

Our initial search identified 301 records. Of those records, 38 were excluded based on screening from title and abstract, 16 studies were assessed for eligibility, and finally 9 original studies were included in our study. The PRISMA flow chart of the study selection can be seen in Figure 1.

## Study Characteristics

There was a total of 9 studies included. Only the ocular manifestations of Zika Virus Infection were reported in original research. Research was found spanning 2016 to 2023. All research originates from

Brazil, Washington DC, South America, and Columbia. The summary of the study was presented in Table 1. All research ocular findings on anterior segment, neuro-ophthalmic, and posterior segment were presented in Table 2

**Table 1.** Summary of Original Articles Regarding Ocular Manifestation and Visual Outcome in Zika Virus

No	Reference	Type of Study	Origin	Sample	Ocular manifestation	Visual Outcome
1	Andrea et al., 2018 <sup>4</sup>	Cross-sectional	Brazil	173 patients	Abnormal visual acuity, ocular motor disorders, visual field defects, low contrast sensitivity, hypoaccommodation, and refractive errors	52 patients poor visual outcome, 40 infants with structural eye abnormalities were present, 14 infants with abnormal visual function had CNS disease, and 5 patients were able to fix and follow
2	Ventura et al., 2016 <sup>5</sup>	Case control	Brazil	3 patient	Macular neuroretinal atrophy	Poor visual outcome
3	Furtado et al., 2016 <sup>6</sup>	Case report	Brazil	1 patient	Uveitis with conjunctival hyperemia bilaterally, bilateral nongranulomatous keratic precipitates, and grade 0.5+ leukocytes in the anterior chamber	20/40 (good visual outcome)
4	Bruno De Paula et al., 2017 <sup>7</sup>	Case series	Brazil	10 patient	Iris coloboma and lens subluxation, focal retinal pigment mottling and chorioretinal atrophy, optic disc hypoplasia and severe optic disc cupping, severe photophobia, gonioscopy showed a white membrane in the peripheral iris extending through Schwalbe's line	Poor visual outcome
5	Shilpa et al., 2017 <sup>8</sup>	Case report	Washington, DC	1 patient	Bilateral posterior uveitis and acquired chorioretinal lesions	20/20 (good visual outcome)
6	Wilkin Parke et al., 2016 <sup>9</sup>	Case report	Brazil	1 patient	Unilateral acute idiopathic maculopathy	3/200 (poor visual outcome)
7	Miranda et al., 2016 <sup>10</sup>	Case series	South America	3 patient	A scattered subretinal hemorrhages external to the macula, retinal vasculature appeared to be absent, with extensive vascular tortuosity, macular lesions of chorioretinal atrophy	Poor visual outcome
8	Freitas et al., 2017 <sup>11</sup>	Case series	Brazil	6 patient	Microphthalmia, inferior complete iris coloboma with a pupillary shape resembling a keyhole was identified	Poor visual outcome
9	Yepez et al., 2017 <sup>12</sup>	Case series	Venezuela, Columbia	43 patient	Hypoplasia of the optic nerve with the double-ring sign, pallor, and increased cup-disk ratio, the macular abnormalities were mild to severe pigment mottling, maculopathy, chorioretinal dysplasia, lesions in the posterior pole, congenital glaucoma characterized by the clinical triad of epiphora, photophobia, and blepharospasm, buphthalmos.	Poor visual function

## Discussion

A flavivirus belong to the family Flaviviridae of the zika virus. Although the Zika virus was isolated from *Aedes africanus* mosquitoes on multiple occasions after it was discovered in 1947, there was initially no evidence that the virus caused human disease. However, a serosurvey of individuals from different regions of Uganda found a seroprevalence of antibodies against the Zika virus of 6.1%, suggesting that human infection was common. Additional serosurveys revealed that

human infection was distributed geographically over a much wider area, including Egypt, East Africa, Nigeria, India, Thailand, Vietnam, the Philippines, and Malaysia. The Zika virus was originally to human illness in Nigeria, 1953 when three sick people were found to have the virus. Only 13 spontaneously acquired instances of the Zika virus were documented during the course of the following 57 years, despite the fact that it was known that infection may cause a mild, feverish illness. The fact that an outbreak in 2007 on multiple islands in the State of Yap, Federated

States of Micronesia, led to an estimated 5000 illnesses among a population of 6700 people, came as a huge surprise.<sup>26</sup>

Ocular abnormalities were discovered in 10 of 29 patients (35%), the majority of the study's microcephalic newborns who underwent thorough ophthalmologic examinations. The most frequent ocular abnormalities included localised pigment mottling, chorioretinal atrophy, and anomalies of the optic nerve (hypoplasia and severe cupping of the optic disc). Foveal reflex loss, macular neuroretinal atrophy, lens subluxation, and iris coloboma have all been seen in this case study and others.<sup>4,12</sup> The research study titled "Ocular Findings in Infants with Microcephaly Associated with Presumed Zika Virus Congenital Infection in Salvador, Brazil" was the first to assess the prevalence of ocular findings in a group of patients with microcephaly and suspected Zika infection during pregnancy. The ophthalmologic findings in three children with microcephaly who were born following the ZIKV outbreak in Brazil. The first ocular abnormalities connected to congenital infections with ZIKV appeared in Recife, Brazil. Arthralgia, malaise, and rash were among the symptoms indicated by seven (70.0%) mothers; of these, six (85.7%) mothers said they manifested during the first trimester.<sup>16</sup> The moms ocular examination revealed no ophthalmologic abnormalities, and they did not report experiencing any ocular symptoms like conjunctivitis while they were expecting. In 15 (75.0%) of the eyes, there were ocular indications of chorioretinal atrophy and/or macular pigment mottling 9 (45.0%) eyes were found to have optic nerve anomalies, such as optic disc hypoplasia, pallor, and/or increased cup-to-disc ratio. The anterior segment structures of all the newborns were normal, however one infant developed horizontal nystagmus. None of the patients displayed inflammatory symptoms such as uveitis or vasculitis.<sup>2,15</sup>

Pathophysiology of the ocular findings cause zika virus infection, shown that zika virus infection is transmitted to fetuses via the placenta and attacks cortical progenitor cells in the brain, causing cell death and impairing neurodevelopment. The study by Van der Pol et al showed that zika virus spreads other parts of the brain, including the visual system (retina, optic chiasm, suprachiasmatic nucleus, lateral geniculate nucleus, and superior colliculus) by axonal transport. After examining the retinas of the infected mice, the presence of zika virus was detected in the retinal ganglion cell layer and inner nuclear layer, where glial cells are most frequently observed. During histological analysis, it was also observed that the glial cells within the optic chiasm and optic tract were abnormal. These findings involving glial cells have made it possible to postulate that glial cells throughout the central nervous system may be the primary target in the pathophysiology of congenital zika virus.<sup>28</sup> The contrary study by Songh et al, evidence that zika virus causes retinal lesions by breaking down the blood retinal barrier and shown that retinal

endothelium and retinal pigmented epithelium are highly permissive and susceptible to zika virus replication and cell death induced by zika virus infection. These researchers suspect that there is direct hematogenic tissue aggression, whereas Van der Pol et al demonstrated affection through axonal transport. The other unknown factors such as viral load, immune response, and genetic susceptibility may play an important role on the manifestations of this disease. <sup>3</sup> A recent study by Caires-Junior et al hypothesized a possible genetic susceptibility after studying 6 sets of nonidentical twins in which only 1 of them presented with congenital zika virus and identified 8 genes that could be related to zika virus infection susceptibility.<sup>1</sup>

The case of a child with congenital zika virus with congenital glaucoma was also described for the first time by de Paula Freitas et al. The child suffered from severe microcephaly, arthrogryposis of the lower extremities on both sides, ventriculomegaly, scattered parenchymal calcifications, corpus callosum dysgenesis, and a streamlined gyral pattern. Chorioretinal atrophy, localised pigmented mottling, and optic nerve hypoplasia were all discovered during a fundus examination of the right eye. Anti-zika virus immunoglobulin M antibodies were present in serum from newborns, while DFV virus immunoglobulin M antibodies and other congenital illnesses were absent. Blood samples from newborns were tested for zika virus RNA, but no RNA was found. The right eye was enlarged with recurrent weeping, irritation, and severe photophobia during an outpatient appointment 95 days after birth. 114 days after birth, the baby underwent a trabeculectomy of the right eye, which normalised the IOP (15 mmHg) and reduced corneal oedema, weeping, and photophobia. Real-time reverse transcription PCR failed to find zika virus-specific RNA attempting to comprehend the retinal layers impacted by the virus's vertical transmission, Ventura et al. assessed infants with an optical coherence tomography (OCT)-based assumed diagnosis of congenital zika virus. OCT imaging was done in nine (82%) of the 16 eyes of the eight infants, who had retinal abnormalities in 11 (69%) of them. In the affected eyes, the main OCT findings included discontinuation of the ellipsoid zone and hyperreflectivity within the retinal pigment epithelium in nine (100%) eyes, retinal thinning in eight (89%) eyes, choroidal thinning in seven (78%) eyes, and colobomatous like excavation involving the neurosensory retina, retinal pigment epithelium, and choroid in four (44%) eyes.<sup>2,28</sup>

Bilateral posterior uveitis with stable visual acuity at 20/20 and the anterior segment was normal bilaterally. The mild vitreous inflammation on the left eye had completely resolved and the result of fundus examination on the right eye remained normal, but the left eye had nasal pigmented outer retinal and choroidal lesions. The patient was treatment on loteprednol etabonate

0.5% ophthalmic suspension three times daily to the left eye and referred to uveitis service, about 1 week after onset of his ocular symptoms and 1 month after his return. Fundus autofluorescence, which revealed hyperautofluorescence, confirming the involvement of the retinal pigment epithelium. At the location of these pigmented lesions, optical coherence tomography (OCT) imaging revealed hyporeflective nodular elevations in the outer retina. Although funduscopy and OCT did not reveal any changes consistent with these locations, indocyanine green dye (ICG) angiography, which is used to examine the choroidal circulation, revealed foci of hyperfluorescence in a confined pattern, consistent with active choroidal lesions, in both eyes.<sup>28</sup> Tears and conjunctival mucus may serve as a reservoir for the Zika virus, according to Zika viral RNA discovered in conjunctival swabs taken from patients up to 7 days after the onset of fever and the tears of inoculated mice. However, it is still not apparent whether the chorioretinal lesions are a result of an immune-mediated process or a direct result of infection.<sup>8</sup>

The differential diagnosis of zika virus congenital zika virus includes congenital infections caused by cytomegalovirus, herpes simplex virus, toxoplasmosis gondii, rubella virus, and syphilis. Nonpurulent conjunctivitis with bilateral non granulomatous anterior uveitis, chorioretinitis, trabeculitis, keratitis, and maculopathy are ocular findings seen in patients with acute zika virus infection. Anatomical and functional changes of the

eye were described in 9 articles, such as anterior and posterior segment abnormalities, extrinsic eye motility and abnormal visual function. Many of these anatomical changes may impact the child's visual function in the future, since they affect prime areas of the eye. Importantly, since the child's first contact with the environment is through eyesight, children with visual impairment commonly experience delayed neuropsychomotor development, which, alongside the syndrome's other signs and symptoms, hinder the child's ability to integrate with his or her surroundings.<sup>4,29</sup>

The initial ocular screening should be performed before hospital discharge or within 1 month and should include fundus evaluation. It is recommended to repeat the ophthalmological evaluation at 3 months of age for those babies with the diagnosis of zika virus infection.<sup>1,2</sup> Recent study by Zin et al, the concern of physicians with regard to the misdiagnosis of zika virus infection cases that 33.3% of the sample screened in Rio de Janeiro, Brazil, presented with funduscopy findings in the absence of central nervous system findings, which infers that we could be missing one third of the affected children. Important to emphasize early assessment and intervention to caring for children with zika virus infection. The results was showed an improvement visual acuity in 62% of infants who received early intervention with eyeglasses for hypoaccommodation and refractive errors.<sup>12,16</sup>

**Table 2.** Summary of Ocular Findings Documented in Zika Virus Infection

No	Segment	Study (n)	Ocular Findings		
1	Anterior	1	Conjunctivitis <sup>13</sup>		
		2	Anterior uveitis <sup>6,14</sup>		
		2	Lens subluxation <sup>2,15</sup>		
		5	Cataract <sup>11,12,16-18</sup>		
		3	Intraocular <sup>11,15,19</sup> calcifications		
		4	Congenital glaucoma <sup>2,11,15,20</sup>		
		4	Microphthalmia <sup>8,18,21,22</sup>		
		1	Corneal ectasia <sup>21</sup>		
		4	Iris coloboma <sup>1,15,19,23</sup>		
		2	Posterior	2	Maculopathy with outer retinal layer and RPE disruption <sup>2,9</sup>
				2	Multifocal choroiditis <sup>2,24</sup>
				2	Macular pigment mottling <sup>1,12</sup>
				2	Chorioretinal atrophy <sup>1,12</sup>
1	Retinal hemorrhage <sup>21</sup>				
1	Vascular tortuosity <sup>16</sup>				
1	Early termination of retinal vasculature <sup>25</sup>				
1	Washed out peripheral retina with hypofluorescent spot <sup>17</sup>				
2	Photoreceptor, RPE thinning with pigment loss, and chorioidal thinning <sup>14,20</sup>				
3	Neuro-ophthalmic			1	Papilledema <sup>17</sup>
		2	Ophthalmoplegia <sup>13,17</sup>		
		1	Ocular flutter <sup>1,26</sup>		
		2	Strabismus <sup>1,27</sup>		
		2	Horizontal nystagmus <sup>10,22</sup>		
		2	Exophoria/esophoria <sup>10,2</sup>		
		2	Loss of pupillary response <sup>10,2</sup>		
		2	Disc hypoplasia, pallor <sup>10,2</sup>		
		2	Enlarged cup-to-disc ratio <sup>10,2</sup>		



## Conclusion

Children with zika virus infection present of ophthalmological abnormalities and high risk for severe visual impairment. Performing ophthalmologic evaluations on children who appear healthy but actually have mother who have laboratory evidence of ZIKV infection during pregnancy. In Suggestion, early diagnosis and intervention, including a personalized rehabilitation program are related to a better visual outcome and quality of life for children with zika virus infection.

## References

- Ventura C V., Maia M, Ventura B V., et al. Ophthalmological findings in infants with microcephaly and presumable intra-uterus Zika virus infection. *Arq Bras Oftalmol* 2016; 79: 1–3.
- De Paula Freitas B, Ventura C V., Maia M, et al. Zika virus and the eye. *Current Opinion in Ophthalmology* 2017; 28: 595–599.
- da Silva Pone MV, Moura Pone S, Araujo Zin A, et al. Zika virus infection in children: epidemiology and clinical manifestations. *Child's Nervous System* 2018; 34: 63–71.
- Zin AA, Tsui I, Rossetto JD, et al. Visual function in infants with antenatal Zika virus exposure. *Journal of AAPOS* 2018; 22: 452–456.e1.
- Ventura C V., Maia M, Bravo-Filho V, et al. Zika virus in Brazil and macular atrophy in a child with microcephaly. *The Lancet* 2016; 387: 228.
- Furtado JM, Espósito DL, Klein TM, et al. Uveitis Associated with Zika Virus Infection. *New England Journal of Medicine* 2016; 375: 394–396.
- Benavides MA, Baldo MB, Tauber S, et al. Case report: Ocular gnathostomiasis in Venezuela most likely acquired in Texas. *American Journal of Tropical Medicine and Hygiene* 2018; 99: 1028–1032.
- Kodati S, Palmore TN, Spellman FA, et al. Bilateral posterior uveitis associated with Zika virus infection. *The Lancet* 2017; 389: 125–126.
- Parke DW, Almeida DRP, Albini TA, et al. Serologically Confirmed Zika-Related Unilateral Acute Maculopathy in an Adult. *Ophthalmology* 2016; 123: 2432–2433.
- Miranda HA de, Costa MC, Frazão MAM, et al. Expanded Spectrum of Congenital Ocular Findings in Microcephaly with Presumed Zika Infection. *Ophthalmology* 2016; 123: 1788–1794.
- de Paula Freitas B, Ko AI, Khouri R, et al. Glaucoma and Congenital Zika Syndrome. *Ophthalmology* 2017; 124: 407–408.
- Yepez JB, Murati FA, Pettito M, et al. Ophthalmic manifestations of congenital Zika syndrome in Colombia and Venezuela. *JAMA Ophthalmol* 2017; 135: 440–445.
- Marquezan MC, Ventura C V., Sheffield JS, et al. Ocular effects of Zika virus—a review. *Survey of Ophthalmology* 2018; 63: 166–173.
- Ventura C V., Ventura LO, Bravo-Filho V, et al. Optical coherence tomography of retinal lesions in infants with congenital zika syndrome. *JAMA Ophthalmol* 2016; 134: 1420–1427.
- Valentine G, Marquez L, Pammi M. Zika virus-associated microcephaly and eye lesions in the newborn. *Journal of the Pediatric Infectious Diseases Society* 2016; 5: 323–328.
- De Paula Freitas B, De Oliveira Dias JR, Prazeres J, et al. Ocular findings in infants with microcephaly associated with presumed zika virus congenital infection in Salvador, Brazil. *JAMA Ophthalmol* 2016; 134: 529–535.
- Ling Man B. Total internal and external ophthalmoplegia as presenting symptoms of Miller Fisher syndrome. Epub ahead of print 2014. DOI: 10.1136/bcr-2014.
- Şahiner F, Siğ AK, Savaşçı Ü, et al. Zika Virus-Associated Ocular and Neurologic Disorders: The Emergence of New Evidence. *Pediatric Infectious Disease Journal*. Epub ahead of print 13 July 2017. DOI: 10.1097/INF.0000000000001689.
- Campos GS, Bandeira AC, Sardi SI. Zika virus outbreak, Bahia, Brazil. *Emerging Infectious Diseases* 2015; 21: 1885–1886.
- de Oliveira Dias JR, Ventura C V., de Paula Freitas B, et al. Zika and the Eye: Pieces of a Puzzle. *Progress in Retinal and Eye Research* 2018; 66: 85–106.
- Zin AA, Tsui I, Rossetto J, et al. Screening criteria for ophthalmic manifestations of congenital zika virus infection. *JAMA Pediatr* 2017; 171: 847–854.
- Karam E, Giraldo J, Rodriguez F, et al. Ocular flutter following Zika virus infection. *J Neurovirol* 2017; 23: 932–934.
- de Paula Freitas B, Zin A, Ko A, et al. Anterior-Segment Ocular Findings and Microphthalmia in Congenital Zika Syndrome. *Ophthalmology* 2017; 124: 1876–1878.
- Jimenez P, Kestelman E, Kestelman B, et al. Multifocal Choroiditis Secondary to Acute Zika Virus Infection. *Ocul Immunol Inflamm* 2020; 28: 952–955.
- Buathong R, Hermann L, Thaisomboonsuk B, et al. Detection of zika virus infection in Thailand, 2012–2014. *American Journal of Tropical Medicine and Hygiene* 2015; 93: 380–383.
- Şahiner F, Siğ AK, Savaşçı Ü, et al. Zika Virus-Associated Ocular and Neurologic Disorders: The Emergence of New Evidence. *Pediatric Infectious Disease Journal*. Epub ahead of print 13 July 2017. DOI: 10.1097/INF.0000000000001689.
- Walker CL, Little MTE, Roby JA, et al. Zika virus and the nonmicrocephalic fetus: why we should still worry. *American Journal of Obstetrics and Gynecology* 2019; 220: 45–56.
- Labib BA, Chigbu DI. Pathogenesis and Manifestations of Zika Virus-Associated Ocular Diseases. *Tropical Medicine and Infectious Disease*; 7. Epub ahead of print 1 June 2022. DOI: 10.3390/tropicalmed7060106.

29. Zin AA, Tsui I, Rossetto J, et al. Screening criteria for ophthalmic manifestations of congenital zika virus infection. *JAMA Pediatr* 2017; 171: 847–854.